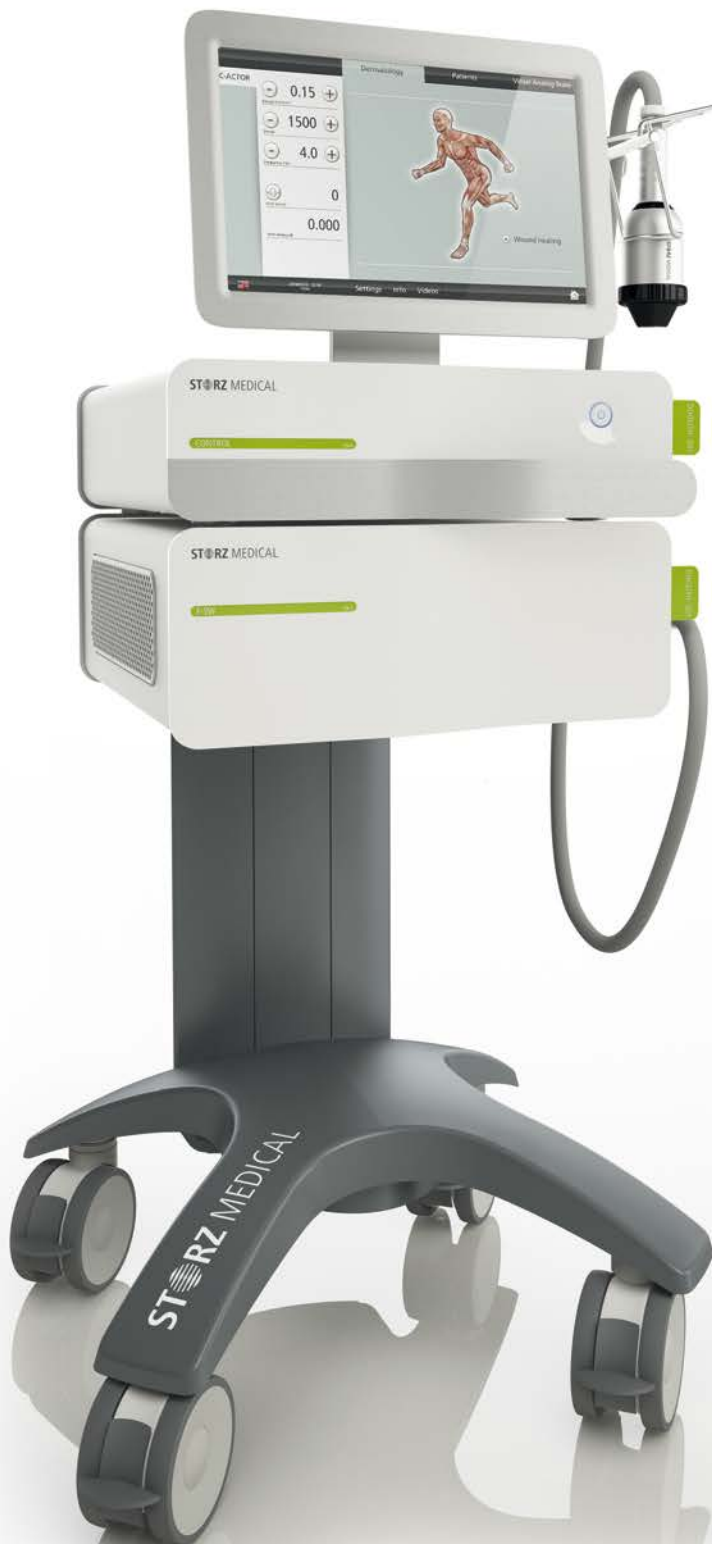

# DUOLITH® SD1

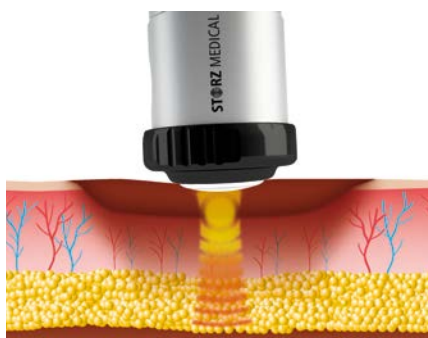
## Wound Healing with Electromagnetic Shock Wave Systems



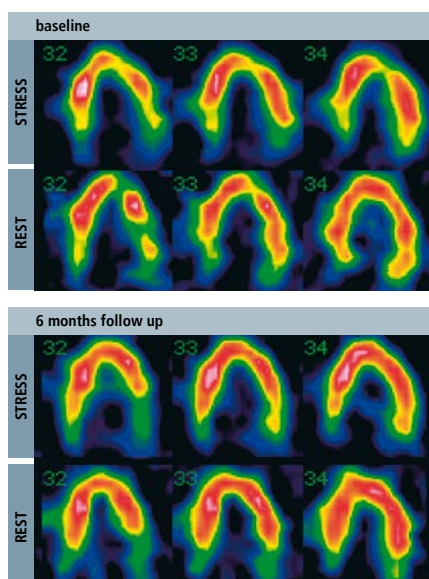
# Electromagnetic Shock Wave Therapy System



Electromagnetic shock wave handpiece



Shock wave treatment of a non-healing wound



SPECT recordings before and 6 months after shock wave treatment document clinical improvements\*

\* Department of Cardiology (Director Prof. Dr. Raimund Erbel), Centre of Internal Medicine, University Hospital of Essen, Germany

## Experiences in wound healing treatment

Clinical experience with shock waves indicates a promising therapy in the field of wound healing. Originally only used for the disintegration of kidney stones, the shock wave treatment of cardiac and orthopaedic indications became a recognized treatment option. Application of low energy shock wave stimulates blood flow and the formation of new capillary vessels (angiogenesis). Internationally, several research groups explore the wound healing using electromagnetic shock wave therapy.

In 2012 Hayashi et al. showed that shock wave therapy enhances skin wound healing in diabetic mice. The study disclosed that eNOS (endothelial Nitric Oxide Synthase) and VEGF (Vascular Endothelial Growth Factor) significantly contribute to the beneficial effect of shock waves in wound healing. Both factors are responsible for the neovascularization and wound closure (see »Literature« on last page).

## About shock wave therapy

### Reliable electromagnetic shock wave generation

The method of electromagnetic shock wave generation is based on the physical principle of electromagnetic induction, as used for example in loudspeakers. The arrangement of coil and membrane is optimized to generate powerful and short acoustic pulses, an ideal form of shock waves for indications close to skin surface, like non-healing wounds.

Electromagnetically generated shock waves are preferably used in the treatment of wound healing disorders. The energy level and the shock wave field warrant an exact treatment of the wound.

## Shock waves initiate healing processes

- Stimulation of microcirculation (blood, lymph) and metabolism (nitrous oxide, vasodilation, reduction of oxidative stress)
- Mechanotransduction – cell matrix stimulation
- Release of NO (eNOS)
- Antibacterial and anti-inflammatory effect
- Stimulation of growth factors (e.g. VEGF)
- Stimulation of stem cells i.e. cell proliferation, transport and differentiation (skin rejuvenation, tissue regeneration)

## Indications

- Non-healing wounds
- Diabetic gangrene
- Ulcera (diabetic)
- Ulcera (non-diabetic)
- Skin burns

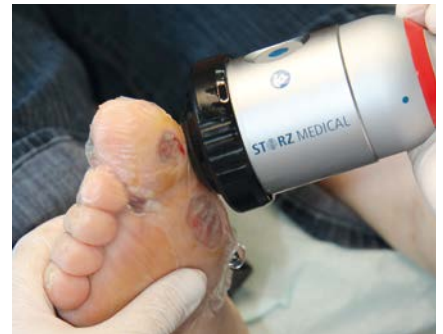## Advantages

- Non-invasive therapy
- Negligible side effects
- No anaesthesia
- Ambulant procedure
- Long lasting effects

## Treatment process recommendation

Number of sessions	Interval (days)	Energy (mJ/mm <sup>2</sup> )	Pulses/session	Frequency (Hz)
3 – 4	7 – 14	0.25	400 + 20/cm <sup>2</sup>	6

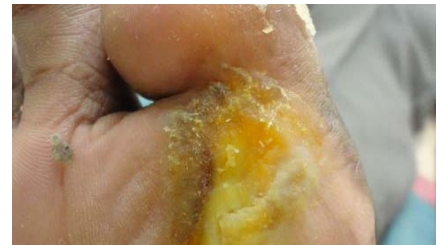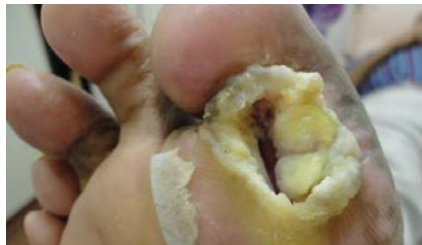1. Depending on the extent and type of the wound parameters can vary.
2. Direct treatment of the wound with a sterile film and ultrasound gel for transmission, additional treatment of upstream tissue.
3. Pre/after documentation (pictures/measurement of wound size)
4. Conservative wound care is typically maintained during shock wave therapy.



The cases shown below are extreme examples and so a higher number of treatment sessions was necessary.

### Case 1: Diabetic trophic ulcer

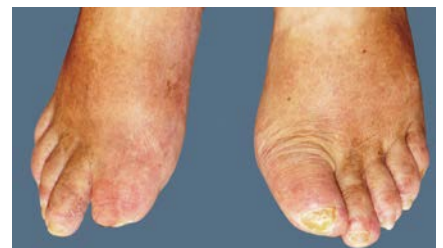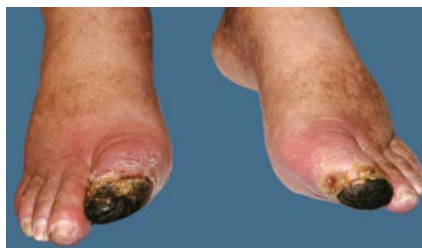- 72 years male patient
- Non-healing ulcer, since 4 years
- Was advised amputation of right 1<sup>st</sup> toe
- 20 treatment sessions during 5 months



Source: Dr Juvekar, Stosswelle Healthcare, Mumbai, India

### Case 2: Diabetic gangrene of the great toes

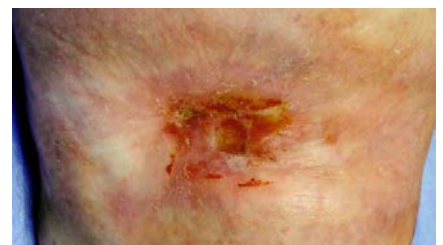
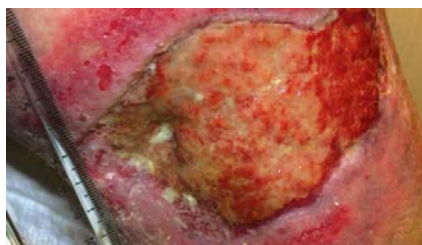
- 75 years male patient
- Non-healing gangrene
- Was advised amputation of both great toes
- In addition to diabetes mellitus II a vascular disease (PAD) exists.
- 18 treatment sessions during 11 months



Source: Dr Jankovic, Cologne, Germany

### Case 3: Non-diabetic chronic venous leg ulcer

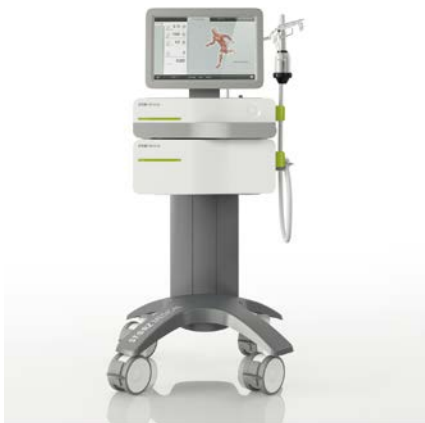- 56 years female patient
- Disease: obesity (60 kg/m<sup>2</sup>), lipedema, lymphedema
- Non-healing ulcer for 6 years
- 30 treatment sessions during 8 months



Source: Dr Stieger, Inselspital, University Hospital, Bern, Switzerland

# Electromagnetic Shock Wave Systems for Wound Healing

## STORZ MEDICAL electromagnetic shock wave systems



### DUOLITH® SD1 »ultra«

#### High-End shock wave system

- Shock wave therapy (C-ACTOR® handpiece): 0.01 – 1.24 mJ/mm<sup>2</sup>
- STORZ MEDICAL »Top View« touch screen display with all relevant information
- Patient management system
- Integrated ultrasound imaging, b/w or colour doppler (optional)
- »Tower« version



### DUOLITH® SD1 »T-Top«

#### Transportable shock wave system

- Shock wave therapy (C-ACTOR® handpiece): 0.01 – 1.24 mJ/mm<sup>2</sup>
- Monitor with touch screen operation
- Easy transport
- »Table Top« version

## Literature



- **Hayashi, D. et al.:** Low-energy extracorporeal shock wave therapy enhances skin wound healing in diabetic mice: A critical role of endothelial nitric oxide synthase. *Wound Repair and Regeneration* 2012, 20(6)
- **Stieger, M. et al.:** Extrakorporale Stoßwellentherapie eines komplizierten chronischen Ulcus cruris venosum. (Extracorporeal shock wave therapy as a treatment of a non-healing chronic leg ulcer.) *Hautarzt*, 2013
- **Jankovic, D.:** Case study: shock waves treatment of diabetic gangrene. *International Wound Journal*, 2011, 8(2)
- **Moretti, B. et al.:** The management of neuropathic ulcers of the foot in diabetes by shock wave therapy. *BMC Musculoskeletal Disorders* 2009, 10: 54.
- **Case 1: Juvekar, R.,** Stosswelle Healthcare, Mumbai, India, 2012